

## 15. INTERVERTEBRAL DISC PROLAPSE

In the elderly lumbar disc prolapse is the most common cause of back pain due to progressive degeneration of the disc nucleus pulposus as a result of ageing. Herniation or protrusion of lumbar disc leading to back pain which may radiate to thigh and legs.

**Most common levels :** L4 –L5 & L5 – S1

### Symptoms

- ◆ Insidious onset of pain
- ◆ Aggravated by activity and relieved by rest
- ◆ Coughing and sneezing aggravate pain
- ◆ Radiation of pain down the posterior thigh, calf upto the foot
- ◆ Parasthesia and tingling of distal extremity

### Signs

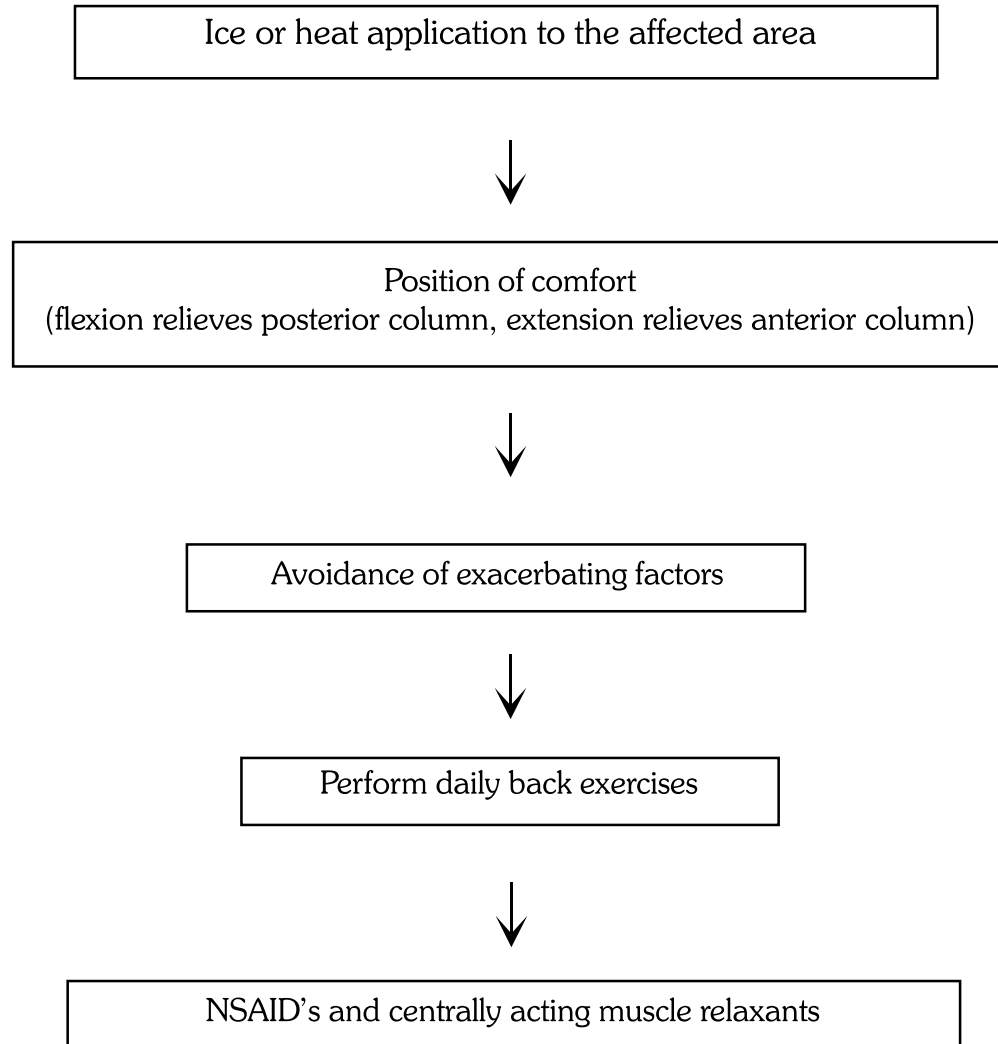
- Pain exacerbated by bending to the affected side
- Range of motion restricted in the spine
- Posturing to avoid pain by bending the trunk away from the affected side and flexing the hip and knee on the affected side
- Nerve root tensioning by straight leg raising (SLR) is positive
- Local tenderness and guarding

### X-ray

Lumbosacral spine AP & lateral

- Spur formation
- Disc space narrowing
- Facet joint degeneration

### **Management guidelines for IVDP**



#### **Exercise indications**

##### **Flexion exercise**

For posterior column disease

- Spinal stenosis
- Facet arthropathy
- Pars defecta

##### **Extension exercise**

For anterior column disease

- ◆ Discogenic pain
- ◆ Vertebral compression fracture